

## Original Article

Taiwan J Ophthalmol 2019;9:27-32

Access this article online
Quick Response Code:

Website: <a href="http://www.e-tjo.org">www.e-tjo.org</a>
DOI: 10.4103/tjo.tjo_6_18

# Utilizing intraoperative aberrometry and digital eye tracking to develop a novel nomogram for manual astigmatic keratotomy to effectively decrease mild astigmatism during cataract surgery

Ming Chen<sup>1</sup>, Michael Reinsbach<sup>2</sup>, Nathan D. Wilbanks<sup>3</sup>, Chaokai Chang<sup>4</sup>,  
Chen Cheng Chao<sup>4</sup>

### Abstract:

**PURPOSE:** The purpose of the study is to develop a novel nomogram and validate with a retrospective comparative study for manual astigmatic keratotomy (MAK) with the assistance of intraoperative aberrometry (Optiwave Refractive Analysis [ORA]) and digital eye tracking (VERION) in mild astigmatic correction enhancement.

**SETTING:** The study was conducted in Honolulu, Hawaii.

**DESIGN:** This was a single-surgeon comparative study with retrospective data collection.

**METHODS:** Sixty consecutive adult cataract surgery cases with regular astigmatism of 1.25 D or less were included for study from April 2016 to April 2017. VERION was used preoperatively in all cases. MAK was performed before phacoemulsification according to the surgeon's own nomogram. ORA then was utilized to obtain the axis and remaining cylinder power after phacoemulsification and intraocular lens implant implantation. MAK extension was performed for eyes with 1 D or more of remaining cylinder. Extensions were carried out slowly and slightly until the amount of cylinder was 1½ D or less under ORA. The mean degrees of extension plus the original MAK plan were calculated to develop the new nomogram. Sixty consecutive similar cases by the same surgeon using the surgeon's nomogram without using ORA/VERION for enhancement were reviewed from April 2015 to April 2016 for comparison. All patients included in this study signed the consent form.

**RESULTS:** Using Alpins vector analysis for comparison, the proportion of patients with cylinder <0.5 D 3 months postoperatively was 87% in the ORA/VERION group compared to 70% in the non-ORA/VERION group ( $P < 0.05$ ). Better than 20/25 best-corrected visual acuity was achieved more in the ORA/VERION group compared to non-ORA/VERION group.

**CONCLUSIONS:** This novel nomogram developed by the surgeon may have better outcomes than the old surgeon's own nomogram. Further prospective control study is needed to validate the efficacy. If validated, those surgeons who do not have ORA/VERION can hopefully use this nomogram with greater success.

### Keywords:

Astigmatism, image-guided system, interferometer, manual astigmatic keratotomy, phacoemulsification

<sup>1</sup>Department of Surgery, Division of Ophthalmology, John A Burns School of Medicine, University of Hawaii, Honolulu, Hawaii, <sup>2</sup>Nassau University Medical Center, New York, NY, <sup>3</sup>Department of Ophthalmology, University of Virginia, Charlottesville, Virginia, USA, <sup>4</sup>Taipei Nobel Eye Clinic, Taipei, Taiwan

### Address for correspondence:

Prof. Ming Chen,  
55 S Kukui St. C109,  
Honolulu, Hawaii 96813,  
USA.  
E-mail: [mingchen@hawaii.rr.com](mailto:mingchen@hawaii.rr.com)

Submission: 01-02-2018  
Accepted: 12-05-2018

This is an open access journal, and articles are distributed under the terms of the Creative Commons Attribution-NonCommercial-ShareAlike 4.0 License, which allows others to remix, tweak, and build upon the work non-commercially, as long as appropriate credit is given and the new creations are licensed under the identical terms.

For reprints contact: [reprints@medknow.com](mailto:reprints@medknow.com)

**How to cite this article:** Chen M, Reinsbach M, Wilbanks ND, Chang C, Chao CC. Utilizing intraoperative aberrometry and digital eye tracking to develop a novel nomogram for manual astigmatic keratotomy to effectively decrease mild astigmatism during cataract surgery. Taiwan J Ophthalmol 2019;9:27-32.

## Introduction

Recent studies have demonstrated that only 55% of patients achieve emmetropia (defined as  $\pm 0.50$  D refractive error) after cataract surgery.<sup>[1]</sup> Over 40% of patients have 1 D or more of astigmatism after cataract surgery.<sup>[2]</sup> Over 75% have  $>0.5$  D before cataract surgery. Manual astigmatic keratotomies (MAKs) are incisions commonly performed at the time of cataract surgery to surgically reduce astigmatic error. There are various nomograms available, but none of them were scientifically developed and validated for efficacy. It is now well known that treating or simply reducing even lower orders of astigmatism during cataract extraction leads to better visual outcomes and improved patient satisfaction.<sup>[3]</sup> MAK has proven to be a safe, effective, and stable procedure for reducing corneal astigmatism during phacoemulsification.<sup>[4,5]</sup> MAK appears most suitable for management of low magnitudes of astigmatism, whereas greater levels of astigmatism are likely best treated by the use of toric lenses, with or without the addition of MAK. In addition, MAKs correct the astigmatism at the source, within the cornea, making them potentially effective for correcting irregular corneal astigmatism where toric lenses are unable to benefit.<sup>[6]</sup> Studies have also demonstrated that even long-term, higher-order aberrations are not induced by MAKs, making them a safe, long-lasting treatment.<sup>[7]</sup> In this single-surgeon analysis, we utilize Optiwave Refractive Analysis (ORA) and VERION, in improving MAK performance to reduce postsurgical astigmatic errors. ORA is an intraoperative aberrometer, which is a relatively new technology now most commonly used to double check the intraocular lens (IOL) power and axis after extraction of the natural crystalline lens and before insertion of the artificial IOL. VERION is also a relatively new device which captures a detailed photograph of the eye and uses limbal blood vessels to uniquely landmark and accurately align the axis of astigmatic error. It is well known that a patient's eye can cyclotort several degrees between the upright and supine position. As measurements are taken with the patient upright and surgeries performed with the patient supine, this has been an increasing concern for suboptimal outcomes. Even a small misalignment can drastically diminish the therapeutic treatment of astigmatism, with a correlation of  $1^\circ$  error decreasing effectiveness by  $\sim 3.3\%$  as Dr. Hill indicated.<sup>[8]</sup> Current manual marking techniques typically identify the horizontal  $0^\circ$  to  $180^\circ$  meridian with different markers in front of a slit lamp.<sup>[2,9,10,8]</sup> Both ORA and VERION were used in this study to help guide location and length of the arcuate incisions beyond what old nomograms might predict.

Despite proven benefits, MAK remains relatively unpopular among cataract surgeons today. There are only

about 15% of American ophthalmologists performing AK either manually or laser assisted according to a 2013 survey by American Society Cataract Refractive Surgery (ASCRS).<sup>[11,12]</sup> One of the reasons many ophthalmologists have not adopted these techniques is believing the less predictable outcome of MAK when compared to toric IOL implants or femtosecond arcuate incisions. There are also potential complications of MAK, which leads to low adoption rates. Potential complications of MAK include foreign body sensation, corneal perforation, globe rupture, and infection. Hirschnall *et al.* indicated in their study that a high eccentricity of the cornea, a large deviation between keratometry and topography, and a high preoperative astigmatism resulted in a larger than expected postoperative astigmatism correction error after AK.<sup>[12]</sup> One study compared toric IOLs to AK in correcting astigmatism during phacoemulsification and demonstrated better outcomes of toric IOLs.<sup>[13]</sup> In another study that compared multifocal toric IOLs and multifocal IOLs with AK, the toric IOLs still showed more predictable outcomes than AK paired with multifocal IOLs.<sup>[14]</sup> Recently, femtosecond laser is being utilized in laser-assisted cataract surgery to perform very precise, live optical coherence tomography (OCT)-driven AKs.<sup>[15,16]</sup> Despite the accuracy of OCT-guided AK with femtosecond laser, there is at least one case report of corneal perforation.<sup>[17]</sup> Infection remains a risk with femtosecond AKs as well. However, these reports were studies on different severities of astigmatism, which are different from this study only for mild levels of astigmatism.

As MAK is simple, effective, time-efficient, and economical for low astigmatic errors, it can be indicated in certain surgical situations such as failure of toric IOL implantation due to posterior capsule rupture, given that sulcus toric IOL is currently not available in the US. Another indication is when some patients simply cannot afford the cost of toric IOL. A recent study on the outcomes of femtosecond laser-assisted AKs was not optimal.<sup>[18]</sup> It is possible those cases may have benefited from intraoperative enhancement by MAK. An interferometer-like ORA and an image-guided system such as VERION are designed to precisely align the astigmatic axis as well as aphakic refractive error. Routine preoperative refractive examinations can lead to a surprising refractive outcome and the reasons can be hidden posterior cornea astigmatism, lenticular astigmatism and abnormality of vitreous or retina. However, future study to validate the nomogram is warranted. The importance of proper localization of the axis of cylinder in toric IOL positioning is clear, but the significance of precise alignment of MAK meridian is not as well studied. Recently, it is gaining interest and was recently reported as an independent predictor for femtosecond AK efficacy.<sup>[19]</sup> Another recent study

has also indicated that a more accurate center axis marking with an image-guided system (VERION) for MAK/limbal relaxing incision (LRI) can result in better cylinder correction similar to the results obtained in implantation of toric IOLs.<sup>[20]</sup> Given this information, we theorize with a pristine cornea and experienced surgeon; VERION and ORA should improve the customization and accuracy of MAK leading to improved outcomes. Consequently, a novel nomogram can be developed accordingly. To our knowledge, there has been no published study to scientifically develop a MAK nomogram. Unfortunately, most of the MAK/LRI nomograms were developed empirically.

## Methods

A control group with a total of 60 consecutive cases with regular astigmatism of 0.5 to 1.25 D with or against the rule (WTR or ATR) had MAKs performed before phacoemulsification by the surgeon without refinement by ORA and VERION. These cases were reviewed from April 2015 to April 2016. Measurements were performed to select the cylinder reading and axis from refraction, keratometry, and topography for astigmatic correction using the following equipment: autorefractometer (Zeiss), topography (Nidek OPD), and IOLMaster (Zeiss). Peripheral corneal thickness was checked to be above 650  $\mu$ m. MAKs were done with a keratome under the microscope according to a nomogram that has been utilized for over 10 years by the surgeon. The blade length of the keratome was preset at 600  $\mu$ m depth, the center of the incision is on the axis of cylinder marked under the slit lamp, and the incision is at the 9-mm diameter of the cornea. Factors predictive of greater AK effect are incision number, incision length, corneal thickness, older age, axis, male gender, superficial cornea condition, corneal hysteresis, and surgeon's experience. These factors were all taken into consideration during the operation.

Next, a total of 60 consecutive cataract cases with regular cylinder of 0.5 to 1.25 D either with or ATR were selected from April 2016 to April 2017. All these cases had alignment of cylinder axis with VERION preoperatively. Peripheral corneal thickness was checked to above 650  $\mu$ m. This was in addition to the same measurements and equipment used in the control group stated previously. MAKs were done using a keratome with the blade length was preset at 600  $\mu$ m before phacoemulsification according to the same nomogram by the surgeon. ORA then was used after phacoemulsification and IOL implantation to determine if there were any remaining astigmatic errors. The quality of the intraoperative ORA measurements was vigorously assessed by the surgeon with careful attention to the ocular surface for appropriate hydration, fixation, and external pressure on the globe.

Intraocular pressures were checked to be around 20 mmHg. MAK was then extended only slightly using the same keratome in both directions according to the ORA measurement and under the VERION guidance for the center of the axis until remaining cylinder determined by ORA was read below or equal to 0.50 D with or ATR. The refraction was again confirmed with three repeated ORA measurements. Three-month postoperative refractions were obtained, and results were compared between the two groups. A successful result was defined as  $\leq 0.50$  D of astigmatism with or ATR without accounting for axis change.

The old nomogram by the surgeon was originally designed to slightly undercorrect the cylinder for the purpose to reduce cylinder conservatively. Therefore, many cases were undercorrected using the old formula, especially for those ATR cases with only one incision. Under the guidance of ORA, we found that the mean additional correction in this group was calculated to be  $5^\circ \pm 2.5^\circ$  without accounting for axis change. As cylinder correction either with toric IOL or MAK cannot be fully precisely corrected due to many variables, this modification of formula is an estimated improvement and is not conclusive. Future prospective control study is needed to confirm this proposed nomogram which is more accurate, and outcomes are better.

## Inclusion criteria

Healthy cornea, 0.5 to 1.25 D of astigmatism, and intact fixation were included in the study.

## Exclusion criteria

Severe corneal disease, Fuchs' dystrophy, keratoconus, pterygium, epithelial basement membrane dystrophy, severe corneal surface disease, media opacity, large vitreous floaters, residual posterior capsule plaque, macular disease, loss to follow-up, optic neuropathy, severe glaucoma, nystagmus, amblyopia, patients unable to fixate as cannot use VERION or ORA,  $>1.25$  D of astigmatism, complex astigmatism, difficult/complicated surgical cases with prolonged phacoemulsification, use of iris hooks intraoperatively, poorly cooperative patients, dementia patients, patients with significant difficulty hearing, retrobulbar/peribulbar anesthesia, or any other treatments to significantly affect patient's fixation were excluded from the study.

## Results

Three-month postoperative refractions were obtained and with Alpins vector analysis showed that the group using ORA and VERION had better correction index (CI) of 0.62 compared to the control CI of 0.41. There was also less magnitude of error (ME) of 0.37 in the ORA/VERION group compared to control ME of 0.51 [Graph 1 and Table 1]. The ORA/VERION group

had more eyes with postoperative cylinder <0.5 D. The proportion of postoperative patients with cylinder < 0.5 D was 87% in the ORA/VERION group versus 70% ( $P < 0.05$ ) in the control group without utilizing ORA/VERION [Graph 2 and Table 1]. Better than 20/25 best-corrected vision was achieved more frequently in the ORA/VERION group compared to non-ORA/VERION group [Graph 3]. In this single-surgeon study involving 120 total patients, outcomes improved by 17% when using both ORA and VERION to customize MAK length and location over the control group which did not utilize ORA and VERION for MAK customization. No intraoperative or postoperative complications occurred in this patient population, including perforation and infection.

This new nomogram from cases of the ORA/VERION group [Tables 2 and 3] was tested favorably by comparison to the former nomogram for statistical difference [Table 1] in the outcomes of cylinder correction. No intraoperative or postoperative complications occurred in this patient population, including perforation and infection.

Mean CI <1 in both groups (indicated under correction) was the intent of the surgeon preoperative using reduced

**Table 1: Alpines vector analysis comparison**

	ORA and VERION (n=60)	No ORA, no VERION (n=60)
Mean TIA	1.1±0.1	1.1±0.1
Mean SIA	0.72±0.1	0.57±0.1
Mean CI	0.62±0.1	0.41±0.1
Mean ME	0.37±0.1	0.51±0.1
Postoperative cylinder <0.50 D (%)	87	70; $P<0.05$

ORA=Optiwave Refractive Analysis, TIA=Target-induced astigmatism (preoperative cylinder), SIA=Surgical-induced astigmatism (surgically corrected cylinder), CI=Correction index, ME=Magnitude of error (remaining postoperative cylinder)

**Table 2: New nomogram**

	1.00-1.25 D	0.50-0.75 D
ATR 58 eyes	45°±2.5° x1 at 9 mm, former was 40°	35°±2.5° x1 at 9 mm, former was 30°
WTR 2 eyes	15°x2 at 9 mm, former was the same	25°±2.5° x1 at 9 mm, former was 20°

\*ATR has only one incision due to cataract surgery main wound made temporally, \*ATR desire slight overcorrection will add 2.5° and WTR desire slight undercorrection due to WTR is more favorable for better vision will minus 2.5°. That is why the correction is different between WTR and ATR, \*Age <60 add 5° for both group. ATR=Against the rule WTR=With the rule

**Table 3: Comparison between the two groups in age, sex and pre-op vision**

	ORA and VERION (n=60)	No ORA, no VERION (n=60) (P)
Mean age	68	64 (>0.05)
Female	34	35 (>0.05)
male	26	25 (>0.05)
Mean preoperative vision	20/70	20/60 (>0.05)

ORA=Optiwave Refractive Analysis

formula to prevent overcorrection which may flip the axis. The outcome goal was to reduce cylinder to below 0.50 D postoperatively.

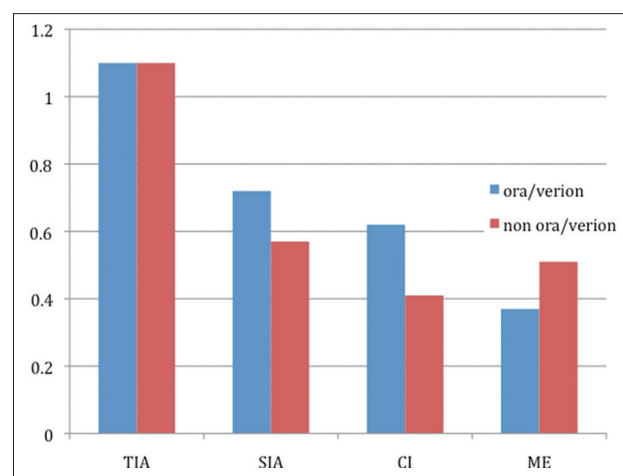
## Discussion

It is difficult to determine exactly anterior cornea or lenticular or posterior cornea or others causing astigmatism preoperatively, despite K reading from refraction, topography, and IOLMaster. Therefore, ORA can be used after cataract extraction and IOL implantation as another reference to determine the remaining astigmatism for MAK to correct.

The strengths of this study are similar patient demographics in age, sex, and preoperative vision between the two groups. In addition, this is a single-surgeon study. The surgeon has over 10 years of experience in performing MAK with over 6000 cases using the same nomogram, same instruments, and in the same surgical center.

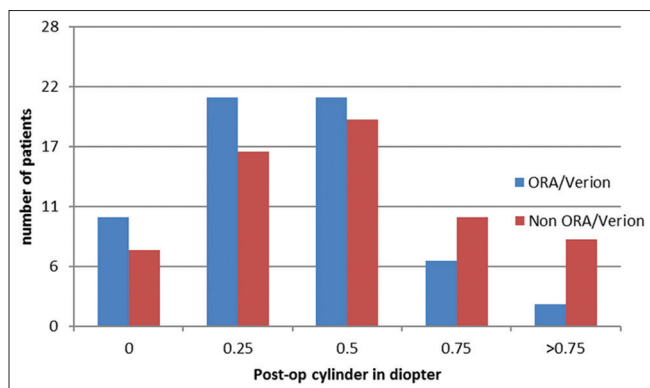
Given that this study is a comparison of a manually performed surgical technique, it has limitations in that it will be difficult to compare among other surgeons who have different experience levels, techniques, use different instruments, and different nomograms. Further limitation is that this study is not prospective control study.

The same technique can also be utilized on AK by femtosecond laser in laser-assisted cataract surgery cases. The most updated study from Harvard using femtosecond laser for AK with a newly developed novel nomogram without ORA and VERION failed to achieve optimal results.<sup>[19]</sup> Their result was 63.4% of cases with postoperative astigmatism of <0.5 D compared to



**Graph 1:** Comparison between two groups in Alpines vector analysis. Y-axis is the diopter of cylinder. X-axis showed ORA/VERION group in blue which had more corrected cylinder (SIA), more CI, and less ME (remaining postoperative cylinder). TIA = Target-induced astigmatism (preoperative cylinder), SIA = Surgical-induced astigmatism (surgically corrected cylinder), CI = Correction index, ME = Magnitude of error (remaining postoperative cylinder), ORA = Optiwave Refractive Analysis





**Graph 2:** Comparison between two groups in postoperative remaining cylinder in diopter

our 87%. They did acknowledge their undercorrection from their nomogram and suggested further modification is needed. In our comparative study, we demonstrated the improvement of undercorrection by CI (from 0.41 to 0.62) with the enhancement assisted by ORA/VERION that later formulated the new nomogram.

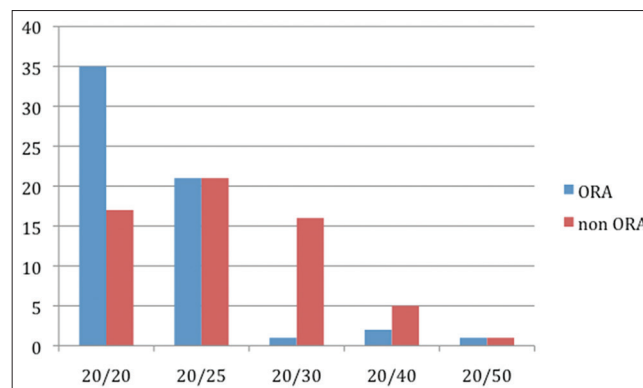
If the residual cylinder is >1.00 under ORA, a MAK can then be performed under ORA to extend or open previous femtosecond produced astigmatic keratotomies until remaining astigmatic error is <0.50 D either WTR or ATR. The cylinder can be reconfirmed with repeated ORA measurements.

We can only assume that our novel nomogram may be better (CI from 0.41 to 0.62) and can be applied to one's practice even without ORA and VERION, especially given that these pieces of equipment are expensive to purchase and maintain. However, due to this is a retrospective study, future prospective study to validate and improve the nomogram is warranted. We believed that this is the first MAK nomogram developed scientifically rather than empirically.

## Conclusions

The assistance of intraoperative aberrometry ORA and digital eye tracking (VERION) for mild astigmatism correction with MAK during cataract surgery demonstrated statistically significant better outcomes than cases without the assistance in this retrospective chart review of a single surgeon. Calculating the added correction after ORA and VERION enabled us to develop a new novel nomogram for surgeons who do not have ORA and VERION. However, future prospective control study is needed to validate the efficacy of this novel nomogram.

This study has been approved by the Institutional Review Board of the University of Hawaii. Declaration of Helsinki has been followed.



**Graph 3:** Comparison for best-corrected postoperative vision between the two groups. Y-axis is the number of eyes; X-axis is the best-corrected vision. Most ORA group eyes in blue had better than 20/25 best-corrected vision. No intraoperative or postoperative complications occurred in this patient population, including perforation and infection

## Financial support and sponsorship

Nil.

## Conflicts of interest

The authors declare that there are no conflicts of interests of this paper.

## References

- Behndig A, Montan P, Stenevi U, Kugelberg M, Zetterström C, Lundström M, *et al*. Aiming for emmetropia after cataract surgery: Swedish national cataract register study. *J Cataract Refract Surg* 2012;38:1181-6.
- Hayden FA. Treating Astigmatism with Arcuate Incisions. *ASCRS Eye World*; February, 2012.
- Khan MI, Muhtaseb M. Prevalence of corneal astigmatism in patients having routine cataract surgery at a teaching hospital in the United Kingdom. *J Cataract Refract Surg* 2011;37:1751-5.
- Carvalho MJ, Suzuki SH, Freitas LL, Branco BC, Schor P, Lima AL, *et al*. Limbal relaxing incisions to correct corneal astigmatism during phacoemulsification. *J Refract Surg* 2007;23:499-504.
- Price FW, Grene RB, Marks RG, Gonzales JS. Astigmatism reduction clinical trial: A multicenter prospective evaluation of the predictability of arcuate keratotomy. Evaluation of surgical nomogram predictability. ARC-T study group. *Arch Ophthalmol* 1995;113:277-82.
- Bradley MJ, Coombs J, Olson RJ. Analysis of an approach to astigmatism correction during cataract surgery. *Ophthalmologica* 2006;220:311-6.
- Monaco G, Scialdone A. Long-term outcomes of limbal relaxing incisions during cataract surgery: Aberrometric analysis. *Clin Ophthalmol* 2015;9:1581-7.
- Hill W. Expected effects of surgically induced astigmatism on AcrySof toric intraocular lens results. *J Cataract Refract Surg* 2008;34:364-7.
- Marques FF, Sato RM, Chiacchio BB, Marques DM, Barreiro J, Caetano RL, *et al*. Evaluation of visual performance and patient satisfaction with pseudophakic monovision technique. *Arq Bras Oftalmol* 2009;72:164-8.
- Ferrer-Blasco T, Montés-Micó R, Peixoto-de-Matos SC, González-Méijome JM, Cerviño A. Prevalence of corneal astigmatism before cataract surgery. *J Cataract Refract Surg* 2009;35:70-5.
- Bethke W, editor. "Surgeons Grapple With the Femtosecond".

- Review of Ophthalmology, 15 March, 2013. Available from: <http://www.reviewofophthalmology.com/article/surgeons-grapple-with-the-femtosecond>.
12. Hirschall N, Gangwani V, Crnej A, Koshy J, Maurino V, Findl O, *et al.* Correction of moderate corneal astigmatism during cataract surgery: Toric intraocular lens versus peripheral corneal relaxing incisions. J Cataract Refract Surg 2014;40:354-61.
  13. Titiyal JS, Khatik M, Sharma N, Sehra SV, Maharana PK, Ghatak U, *et al.* Toric intraocular lens implantation versus astigmatic keratotomy to correct astigmatism during phacoemulsification. J Cataract Refract Surg 2014;40:741-7.
  14. Gangwani V, Hirschall N, Findl O, Maurino V. Multifocal toric intraocular lenses versus multifocal intraocular lenses combined with peripheral corneal relaxing incisions to correct moderate astigmatism. J Cataract Refract Surg 2014;40:1625-32.
  15. Day AC, Lau NM, Stevens JD. Nonpenetrating femtosecond laser intrastromal astigmatic keratotomy in eyes having cataract surgery. J Cataract Refract Surg 2016;42:102-9.
  16. Rückl T, Dexl AK, Bacherneegg A, Reischl V, Riha W, Ruckhofer J, *et al.* Femtosecond laser-assisted intrastromal arcuate keratotomy to reduce corneal astigmatism. J Cataract Refract Surg 2013;39:528-38.
  17. Cherfan DG, Melki SA. Corneal perforation by an astigmatic keratotomy performed with an optical coherence tomography-guided femtosecond laser. J Cataract Refract Surg 2014;40:1224-7.
  18. Chen M, Seagrave Z, Chen J, Patrianakos T, Dwarakanathan S. A pilot study to compare using verion imaging guided system (Alcon) to manual marking in assisting lri (limbal relaxation incision) to reduce cylinder power in cataract surger. Int J Open Access Ophthalmol 2016;1:4.
  19. Day AC, Stevens JD. Predictors of femtosecond laser intrastromal astigmatic keratotomy efficacy for astigmatism management in cataract surgery. J Cataract Refract Surg 2016;42:251-7.
  20. Baharozian CJ, Song C, Hatch KM, Talamo JH. A novel nomogram for the treatment of astigmatism with femtosecond-laser arcuate incisions at the time of cataract surgery. Clin Ophthalmol 2017;11:1841-8.

